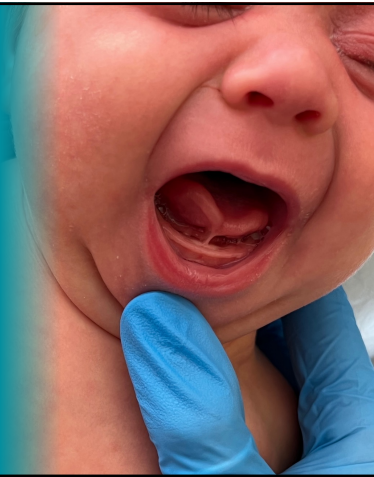

# Is it a Problem for Infant Feeding?



1



2

## Understanding the terminology

Lingual Frenulum	(or Frenum) The mucous membrane fold found underneath the tongue
Labial Frenulum	Tethering under the upper lip – commonly referred to as a lip-tie!
Genioglossus	Tongue muscle
Ankyloglossia	'Stiff tongue' (Bent, crooked, stiff, fused, fixed, closed)
Tongue-tie	Ankyloglossia – limited tongue movement

3

## Understanding the terminology

### Frenotomy

Lingual frenotomy is a surgical procedure that divides the lingual frenulum (Baker, 2015)

Frenotomy	American
Frenulotomy	English
Frenectomy	The removal of the frenulum

4

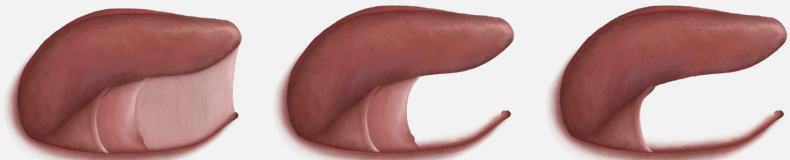
In 200 babies studied, all but one had an observable or palpable frenulum

(Haham et al., 2014)

The key is to understand what is 'normal'

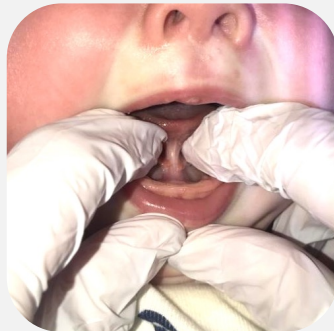
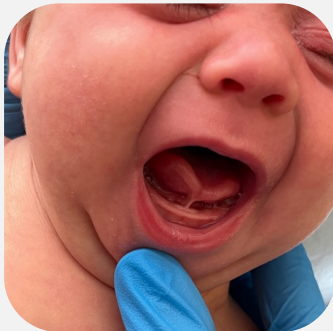
5

Anterior V's Posterior!



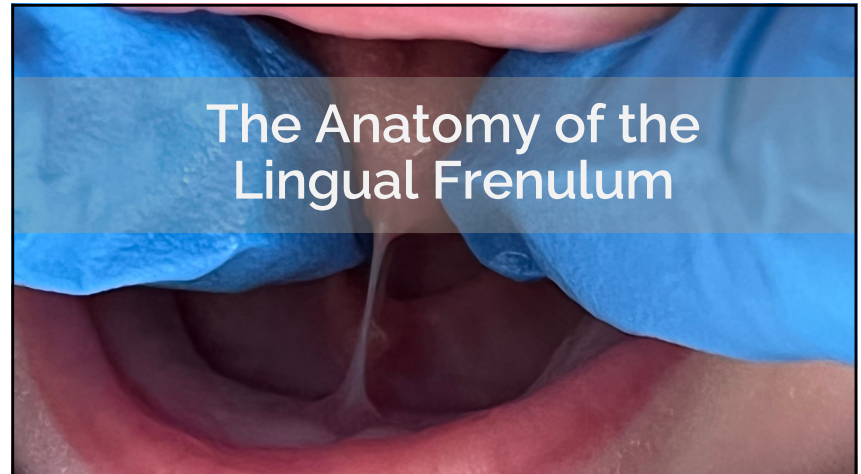
6

Anterior V's Posterior!



7

The Anatomy of the Lingual Frenulum



8

## What does it consist of?

Mucous Membrane

Fascia ~ Connective Tissue

Genioglossus Muscle = Tongue Muscle

9

## Common terms

~~Submucosal Band~~

~~String~~

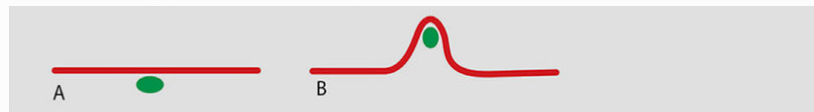
~~Cord~~

~~Mass~~

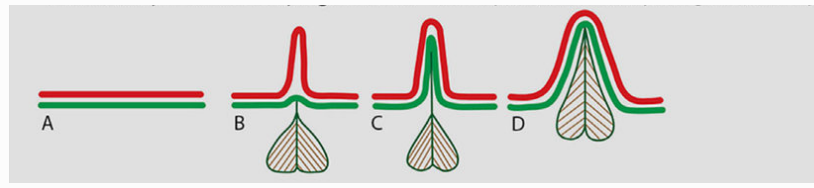
It is a midline FOLD of Fascia, not a Band!

10

1. Presumed popular model of lingual frenulum structure: a submucosal band



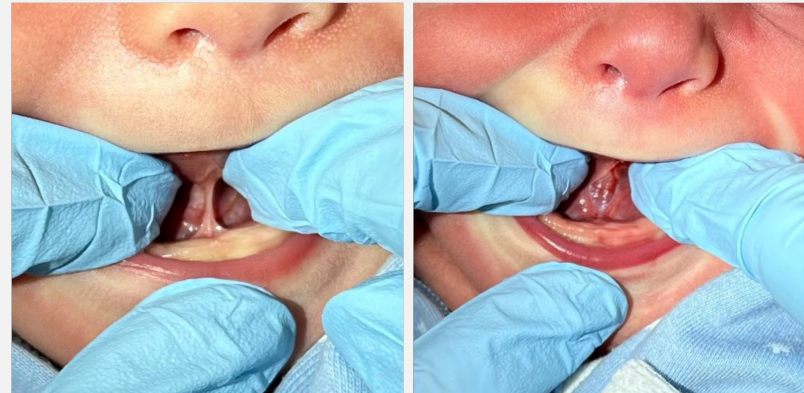2. New evidence based understanding of lingual frenulum structure:  
A fascial layer with overlying mucosa – with explanation for morphological variability



11

Before

Post Frenulotomy



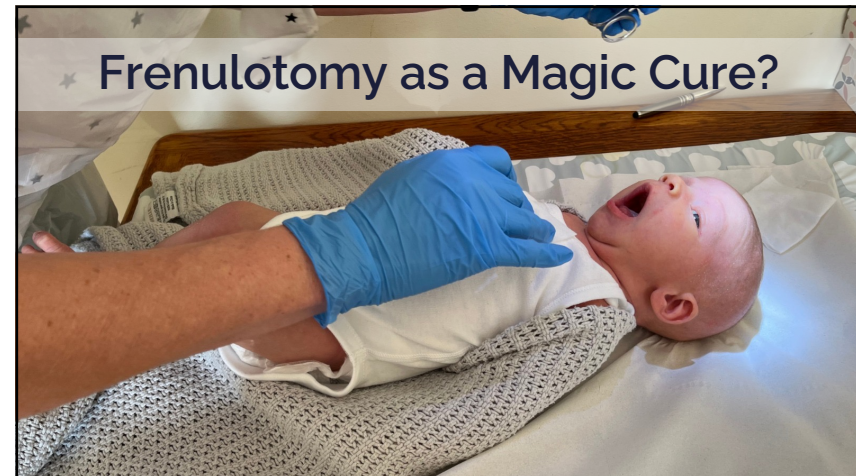12

## Referring for further support:

- ~ Lactation Consultants of Great Britain  
<https://lcgb.org/>
- ~ The Association of Tongue-tie Practitioners  
<https://www.tongue-tie.org.uk/>
- ~ The Association of Tongue-tie Practitioners Facebook group for parents and healthcare professionals  
<https://www.facebook.com/groups/ATPpublic>



13



14

## Advanced Practitioner Training

## Accredited Tongue-tie Assessor Award



Understanding Tongue-tie:  
The Complexities of Definition and Diagnosis

15